

OSCE

JCM

Dr Tommy Lam

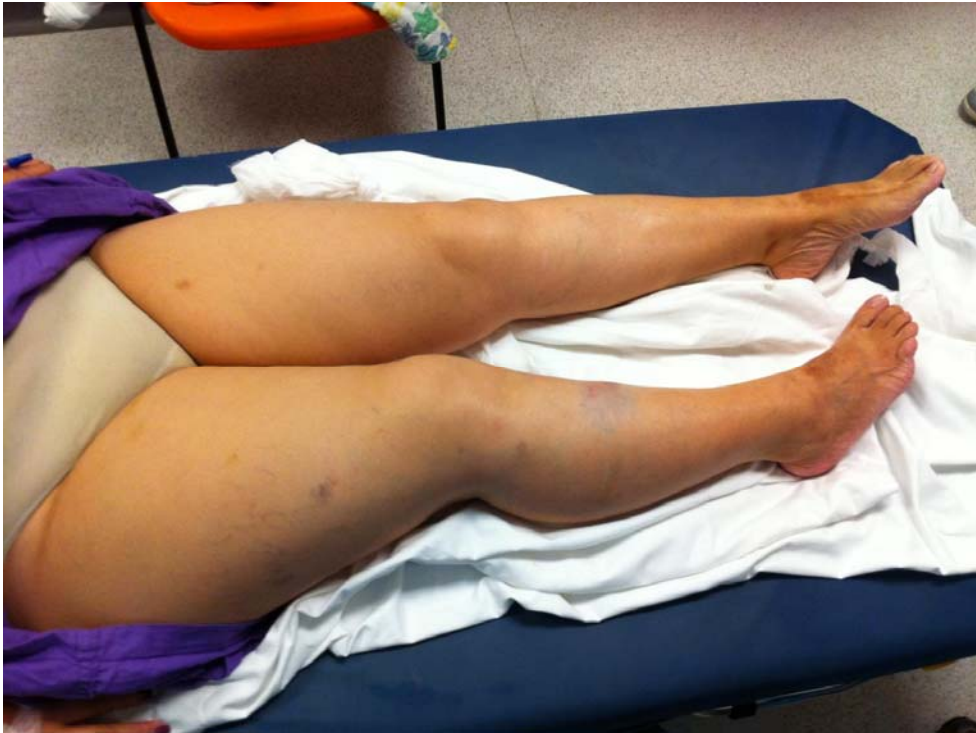POH

7th Dec 2011

Q1

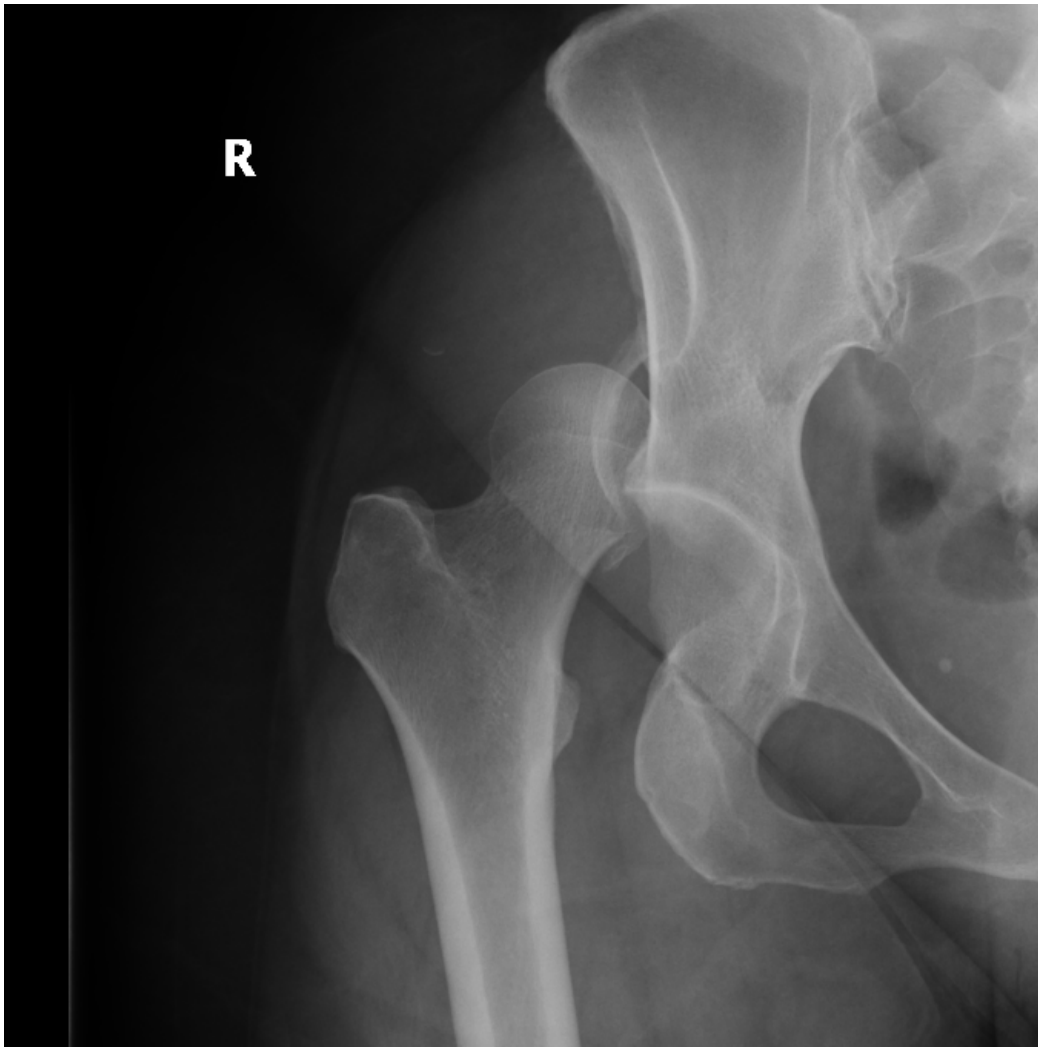
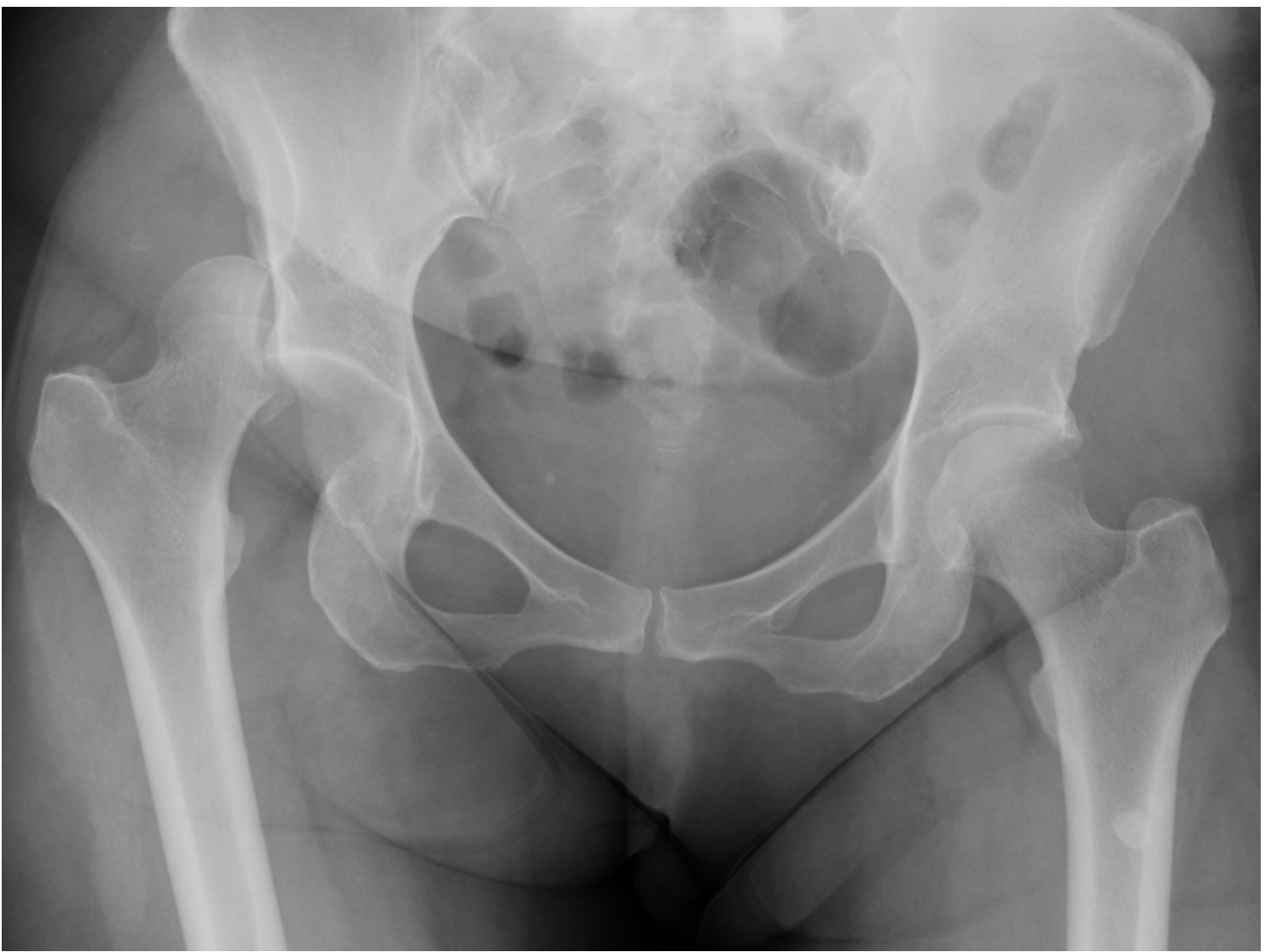- F/40 year old lady
- Driver in a MVC case
- Seat belt used
- Vital sign stable
- Complain of right hip pain, can't walk

Q1



Q1

1. Describe the positive physical finding?
2. What differential diagnosis, list two?



Q1

3. What is the diagnosis ?
4. What is the name of reduction method
5. What medication will you use before procedure ?
6. How to do it ?
7. How to test the sciatic nerve injury ?

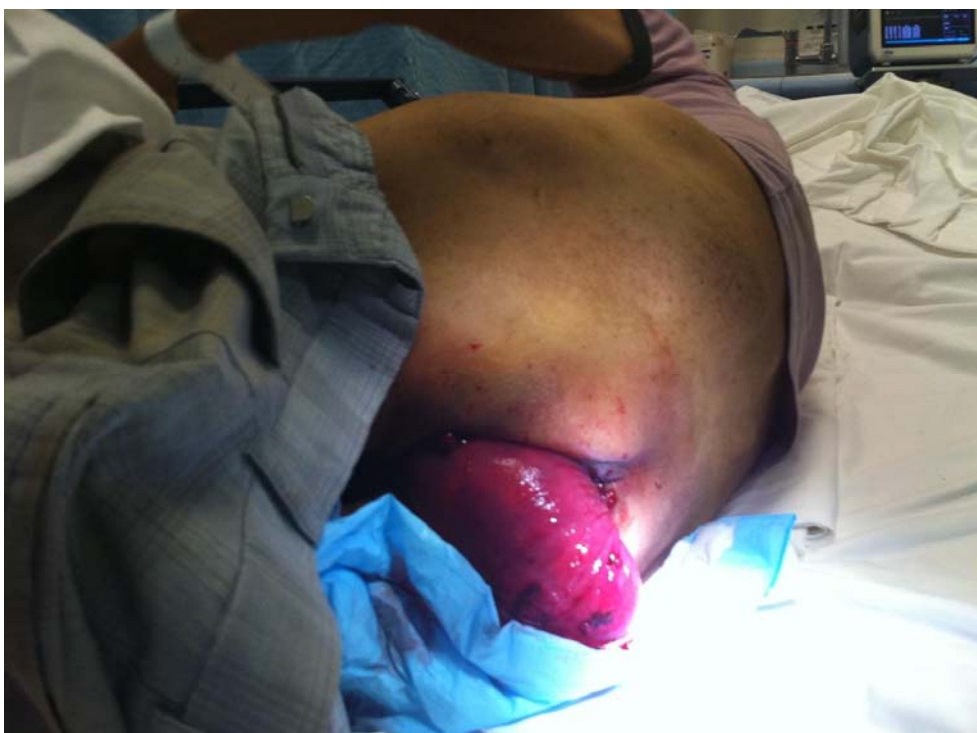Q2

- A 60 year old gentleman present with anal pain for 1 day
- Vital sign stable
- Afebrile
- No trauma history

Q2

1. What are the differential diagnosis, list three ?

Q2



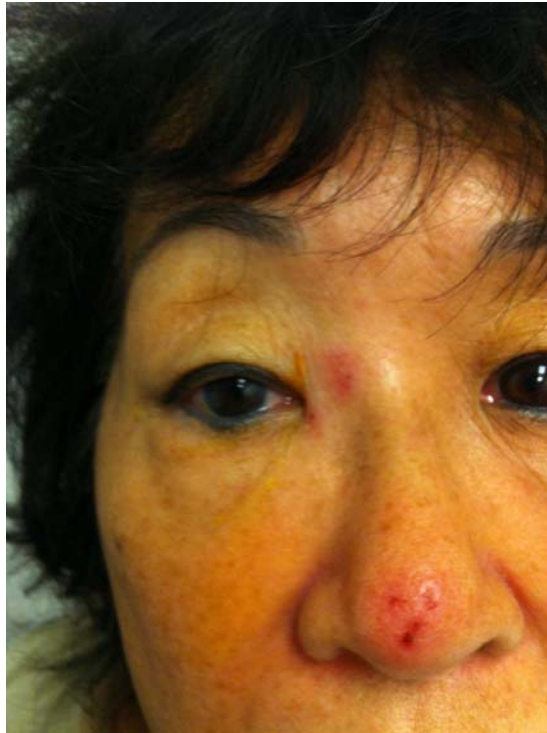Q2

2. What is the potential complication ?
3. What is the treatment in AED ?

Q3

- 60 years old lady
- Complain of painful skin rash over right side of face
- Vital sign stable

Q3



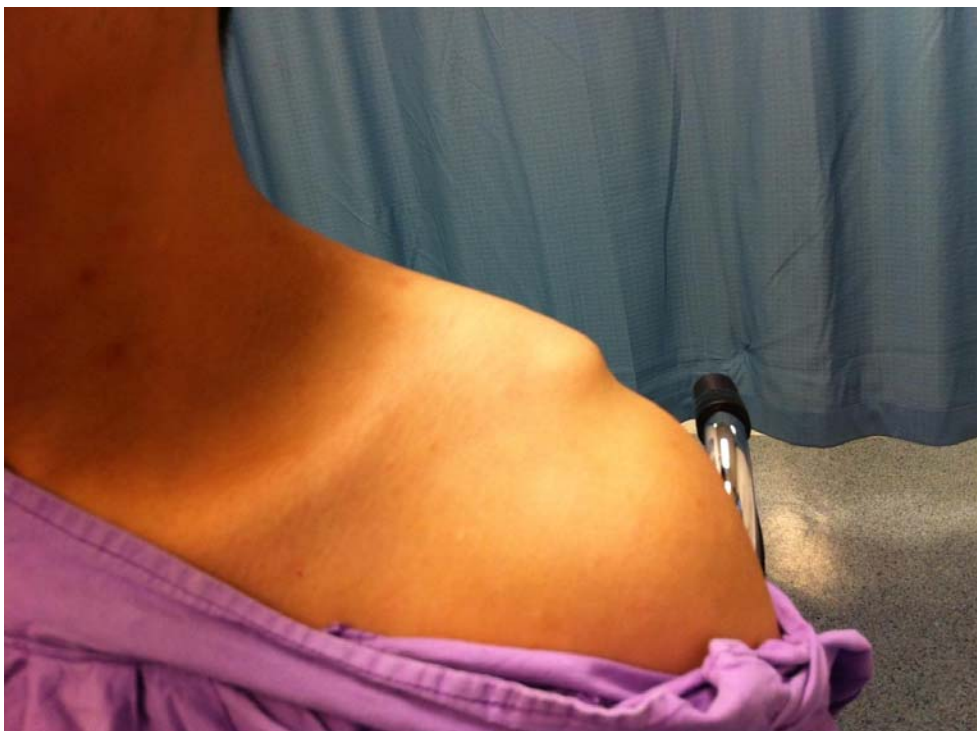Q3

- What is the name of this sign?
- What is the diagnosis ?
- Which branch of nerve involved ?
- Which part of organ you need to exam ?
- What is the typical lesion you need to look for if it is involved ?

Q4

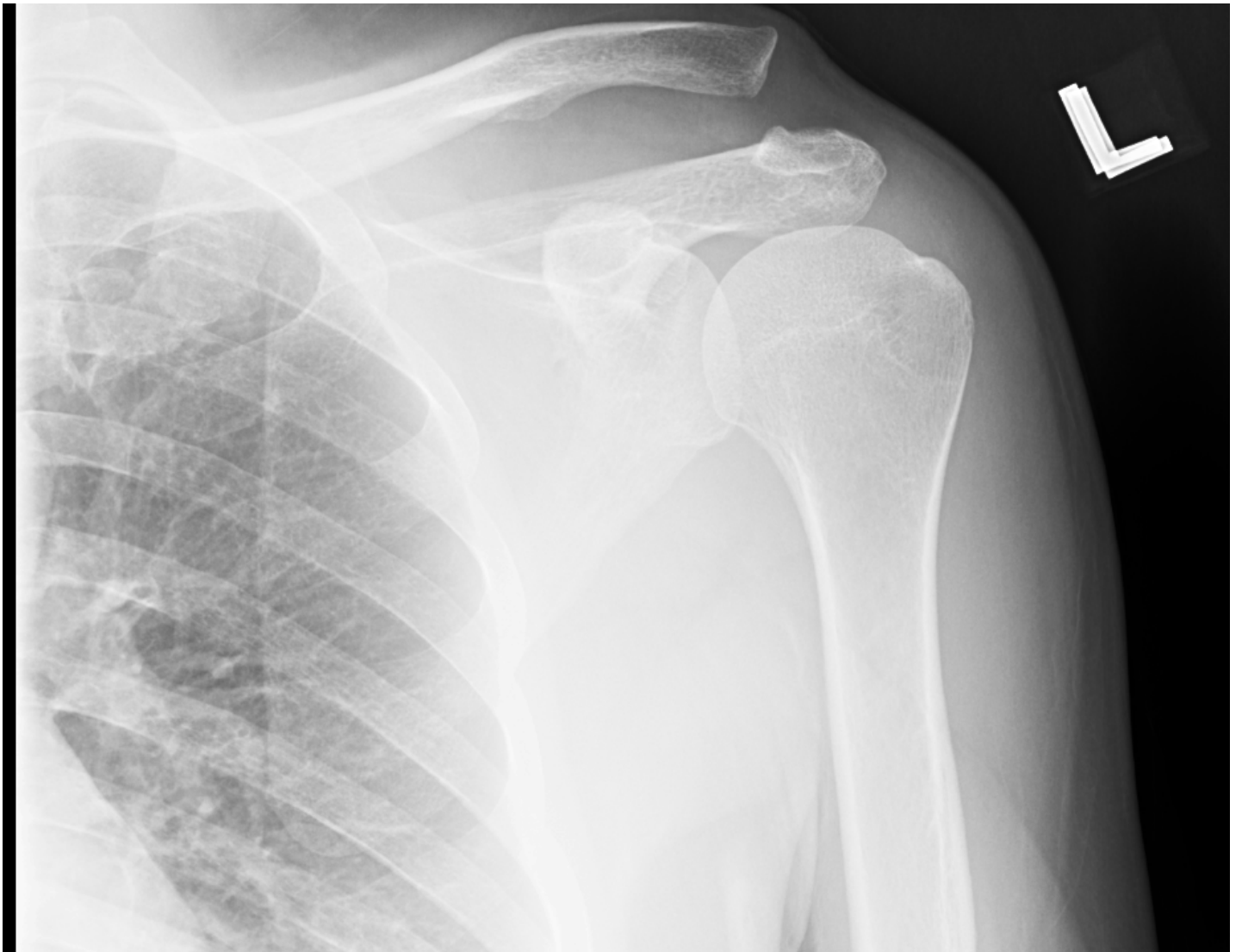
- A 20 years old gentleman suffer from fell from bicycle and land on left shoulder

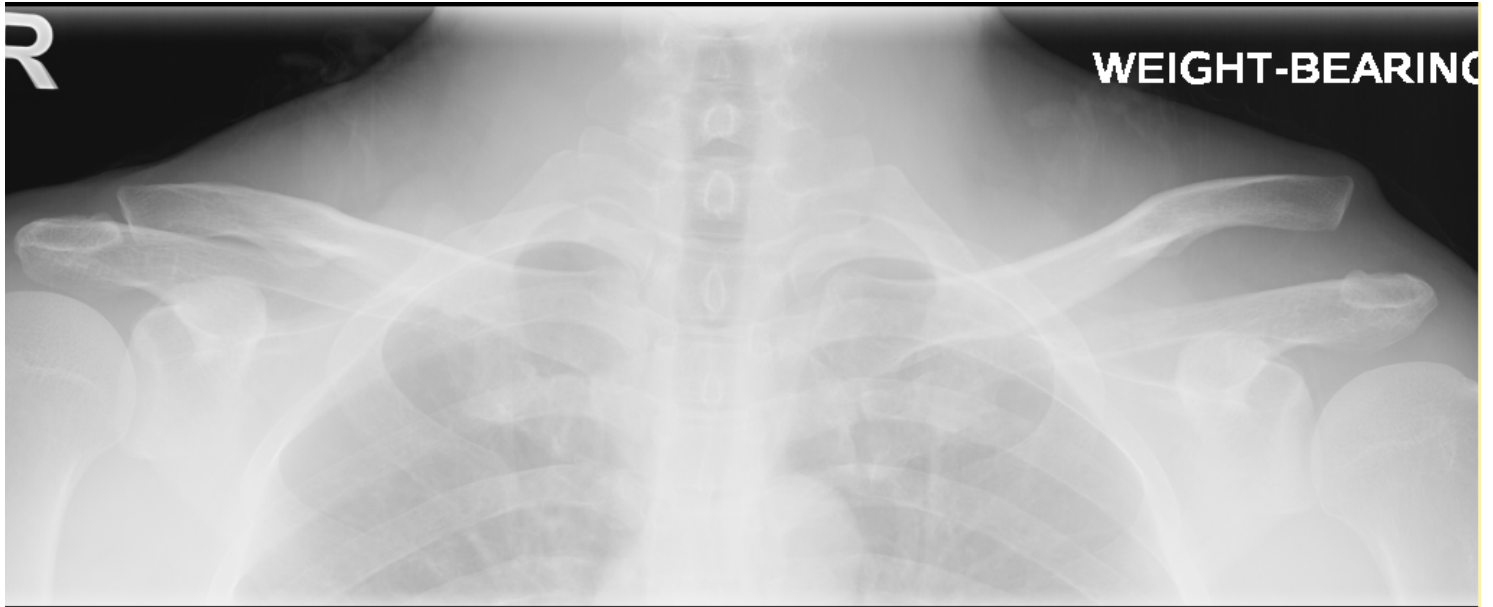
Q4



Q4

1. Describe the physical finding.
2. What is the differential diagnosis, list three?





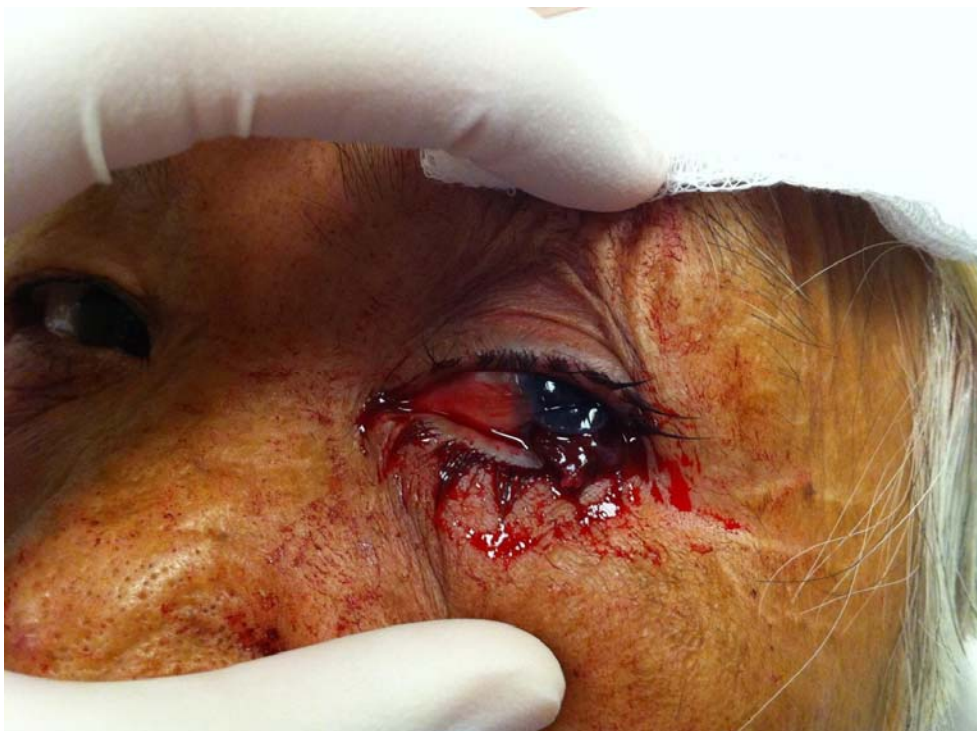Q4

- Describe the finding in Xray.
- What is the diagnosis ?
- What is the name of classification ?
- Which type does it belong?

Q5

- A 80 years old lady with history of left cornea ulcer with surgery done 10 years ago
- Present to AED for injury over her left eye

Q5



Q5

1. Describe what you see?
2. What is the management?
3. What imaging need to arrange and what do you look for ?
4. What is the complication?

Q6

- 20 year old lady
- Suffer from acute delirium, 1 hour after herbal broth for skin condition
- BP 128/75, Pulse 120/min
- Temp 38.1
- Pupil 4mm, bowel sound sluggish
- Clinical: anticholinergic toxidrome

Q6

姓名 羅小明 年齡 50

白芷 野菊花 公英 地丁 川芎
透骨草 天葵子 吸百 龍舌草
合歡花 合歡皮 吸百 龍舌草
丹 吸生 地丁 百部 文 蒼子 吸
春砂仁 佛手 吸百 龍舌草
小兒參 吸

CJAS

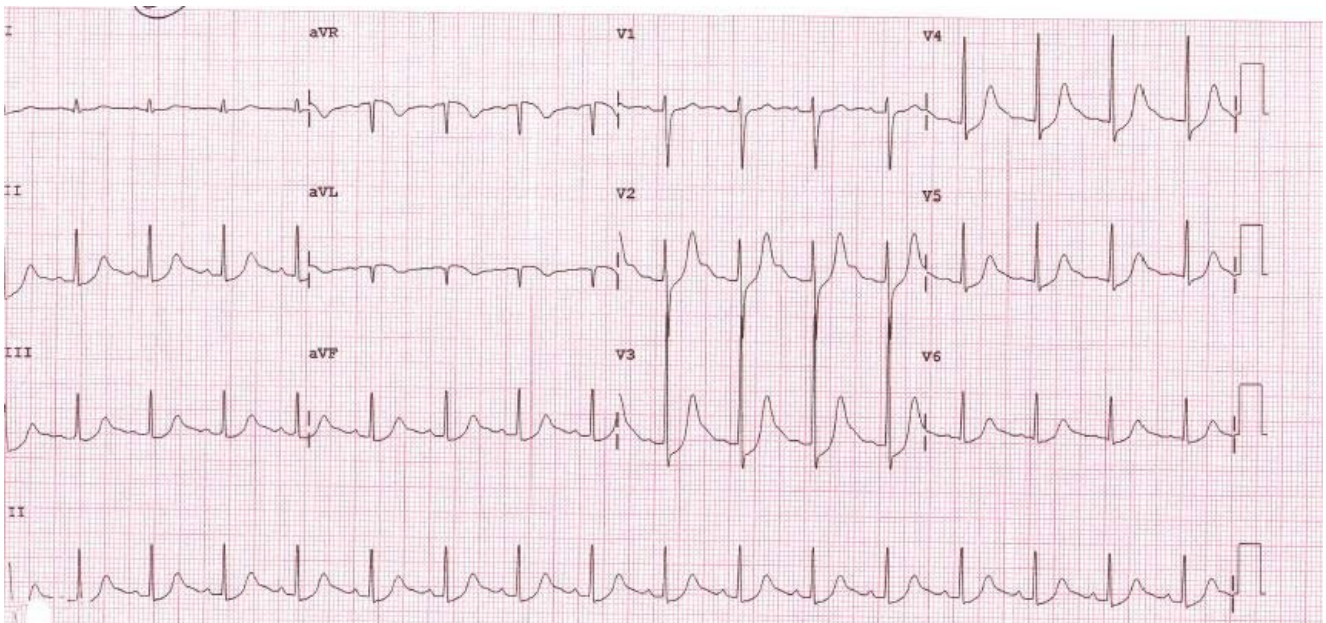
Q6

- What herb is likely being substitution in this broth?
- Usually it is substituted by _____ ?
- What is the antidote ?
- What is the potential side effect of this antidote ?
- What medication is used for this side effect ?

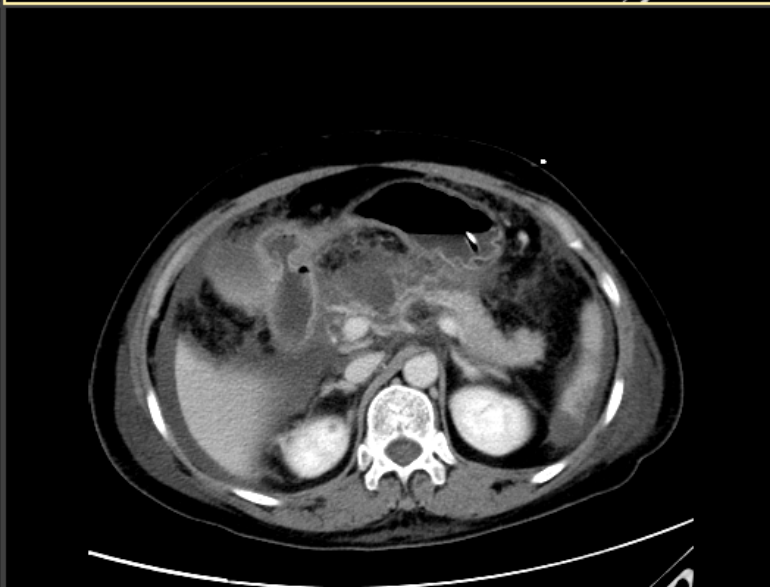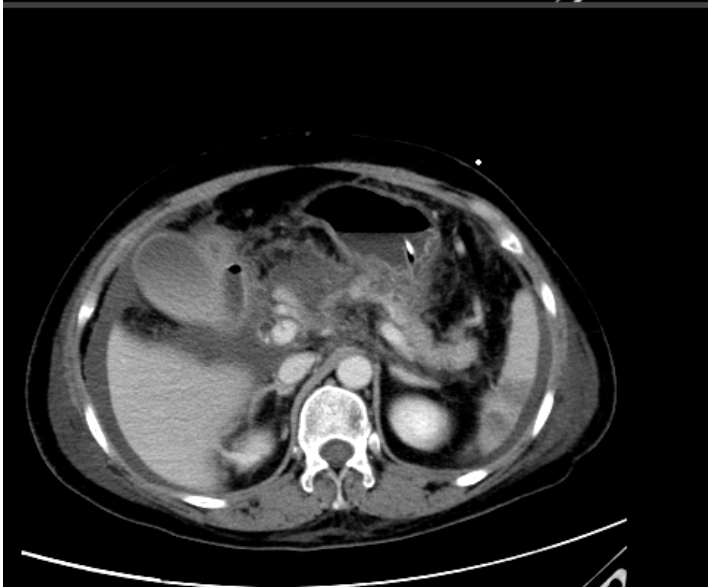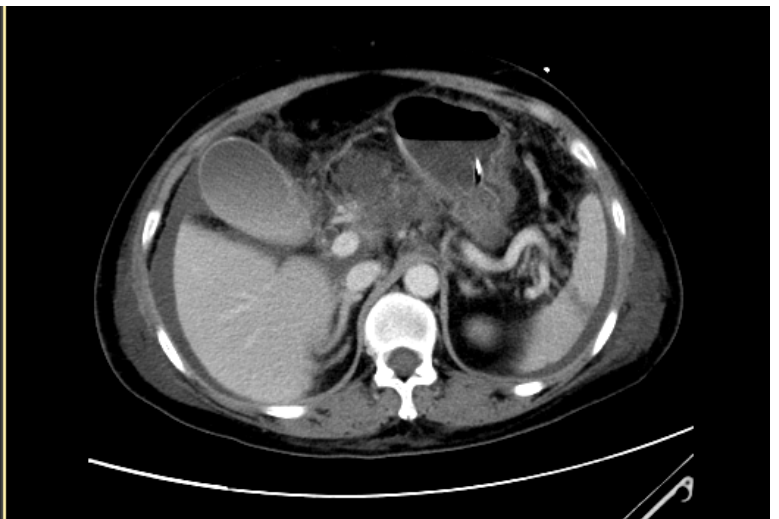
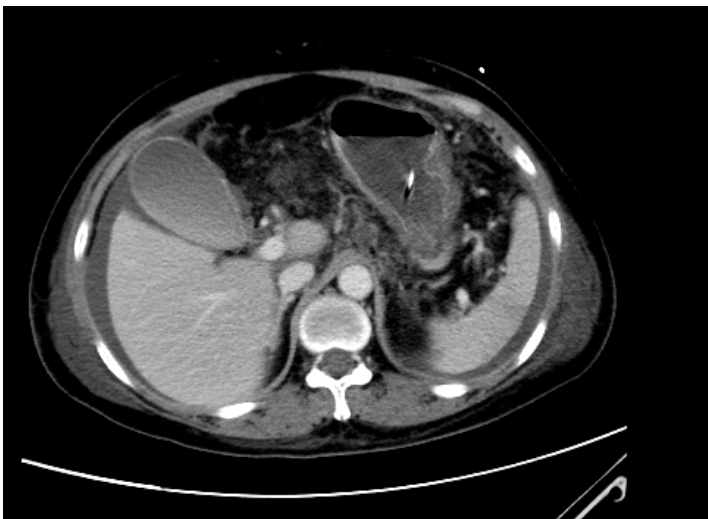
Q7

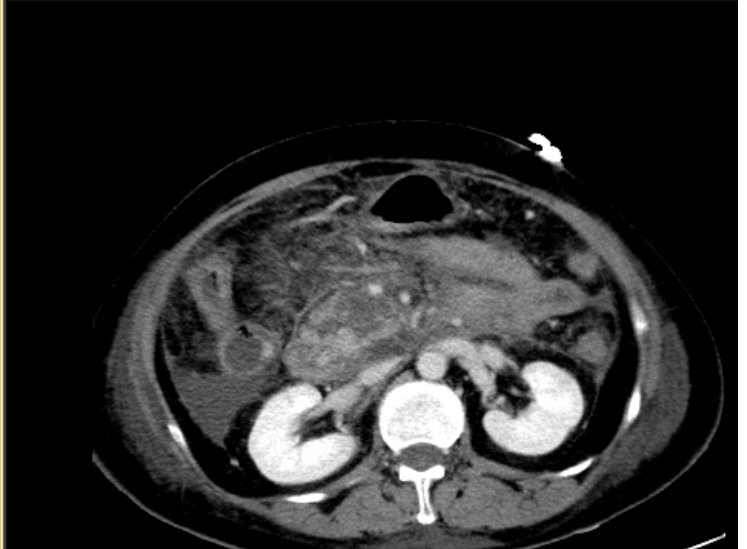
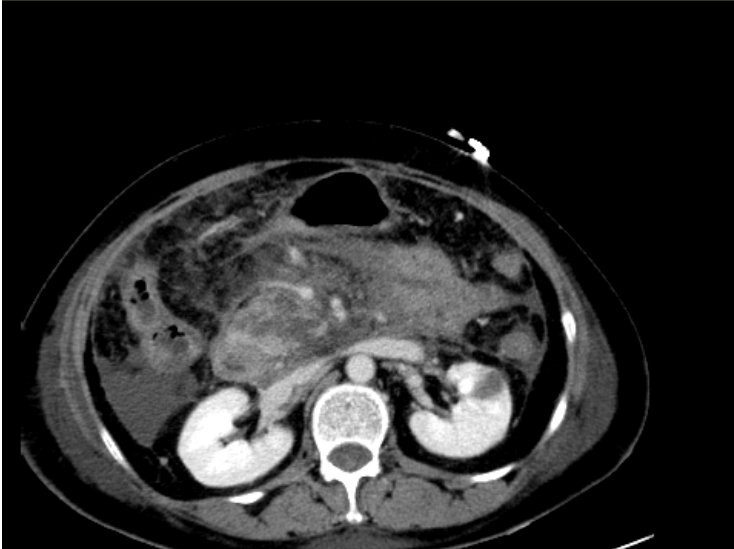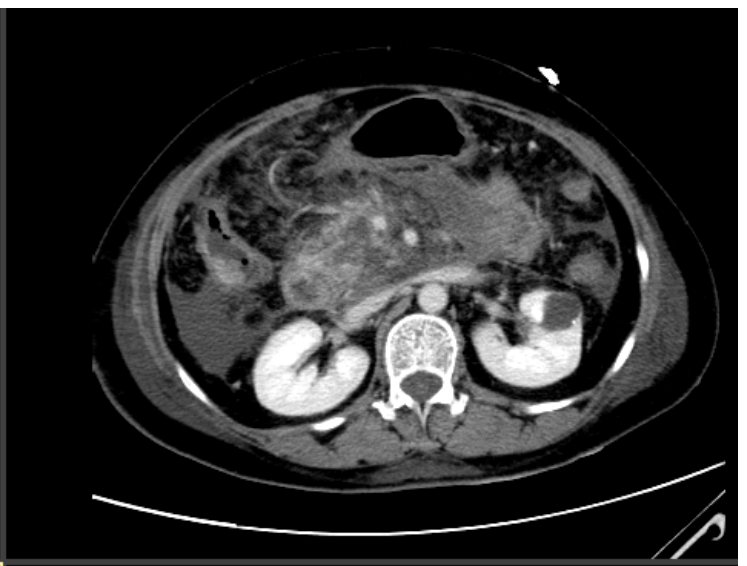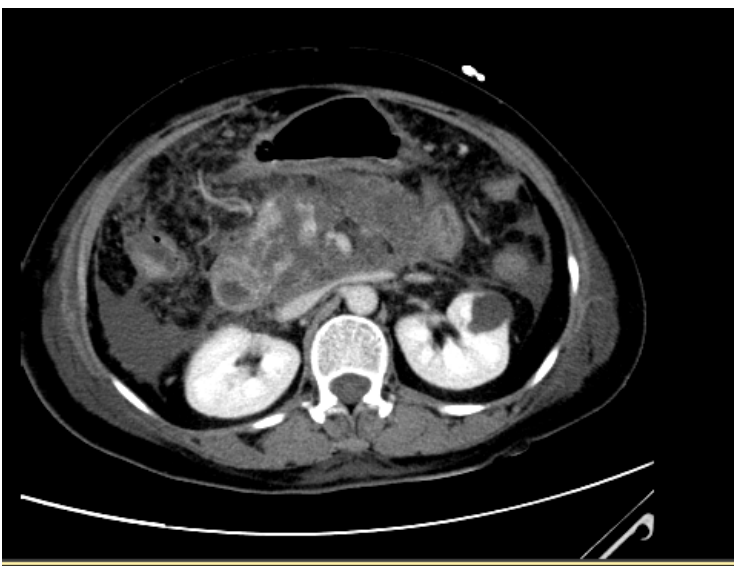
- 61 years old lady
- Chronic alcoholism
- Complain of epigastric pain and vomiting
- ECG was done

ECG



- Comment on the ECG
- What is the possible underlying cause ?
- CT abdomen done, please comment





- Blood for amylase : 5012
- Can you link up the patient condition and explained the ECG changes ?